

Diamond Wire for Complete Subcision

Dr. Miles Graivier, FACS
Private Practice
North Atlanta Plastic Surgery

Treatment of lines, folds depressions, scars, adhesions

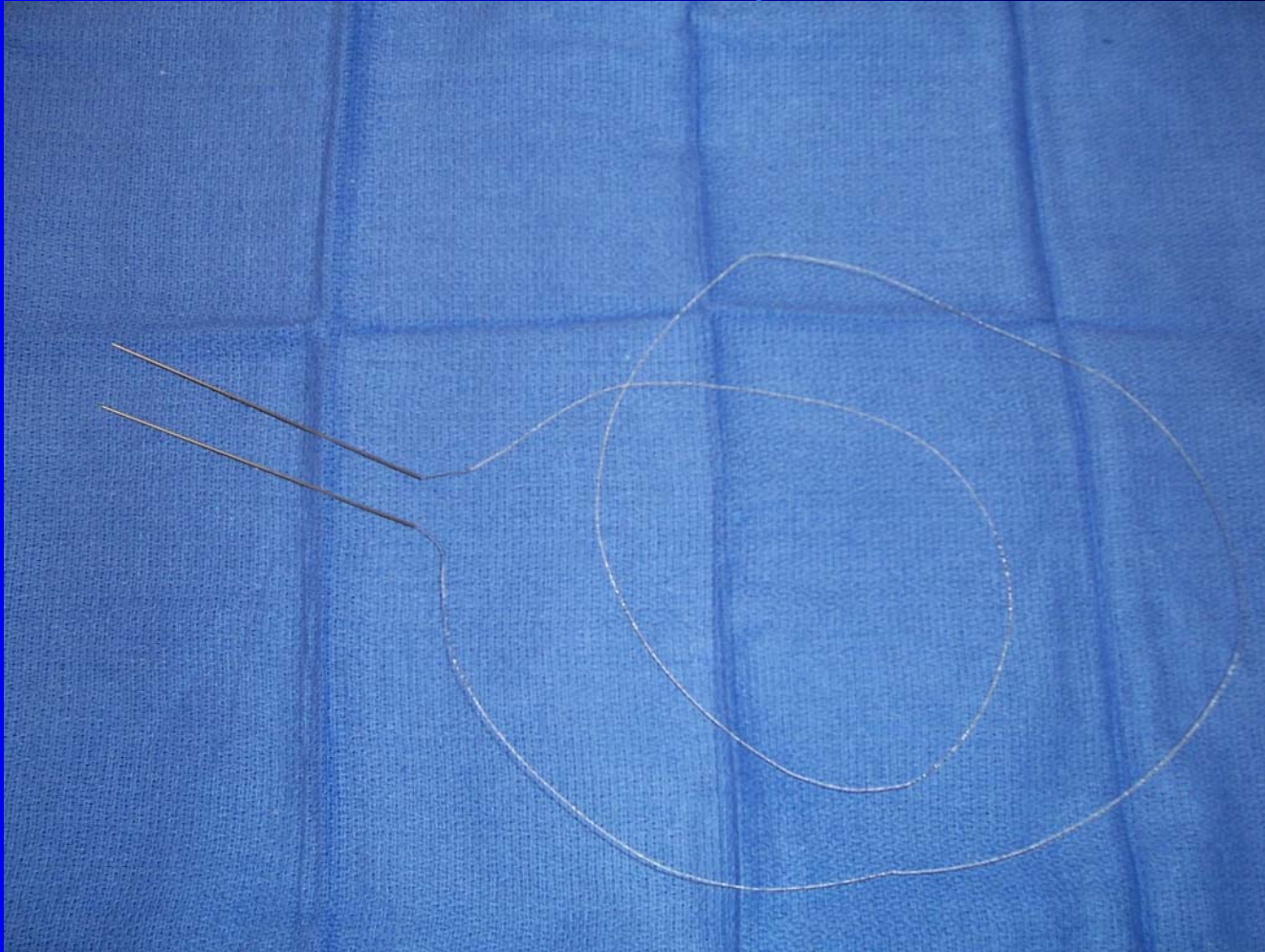
- The “ R’s “ of rejuvenation:
 - Refill, relax, resurface, retighten, redrape
& now
- **RELEASE**

Diamond Wire

- 7 strand Braided Wire with double ended Keith (straight) needles
- Insert under dermal attachments through needle punctures and come out same puncture site
- **Complete** release of lines, wrinkles, folds

**Better than other forms of Subcision*

Diamond Wire



Diamond Wire

- May Resurface skin at same time as subcision
- Can inject Fat or other filler, or place graft after subcision
 - *May not be necessary in all cases*
 - *Do not overcorrect*

Diamond Wire

- Areas of use:
- (Dr. Graivier's Series: **23 pts**; 12 month follow-up 5/2005)
 - Nasolabial Folds (WSRS 4 and 5) 18 pts
 - Marionette lines 7 pts
 - Radial lip lines/ White roll 5 pts
 - Cheek, chin lines 5 pts
 - Glabellar lines 5 pts
 - Acne scars 2 pts
 - Corner of mouth 3 pts
 - Depressed scars (Body/ Face) 4 pts
 - Labiomenal groove 2 pts
 - Transverse forehead lines 2 pts
 - Neck lines 1 pt

Diamond Wire Series (Dr. Miles Graivier)

- 23 patients: 12 month longest f/u (5/2005)
 - 16/23 : Simultaneous fat injection
 - 5/23 : Simultaneous laser resurfacing
 - 1/23 : Simultaneous Radiesse injection
 - 1/23 : Simultaneous Alloderm placement
 - 5/23 : Nothing placed after release


Diamond Wire: Complications

- Hematoma : 1 pt
- Localized abscess: 1 pt
- Overcorrection (with fat): 3 pts

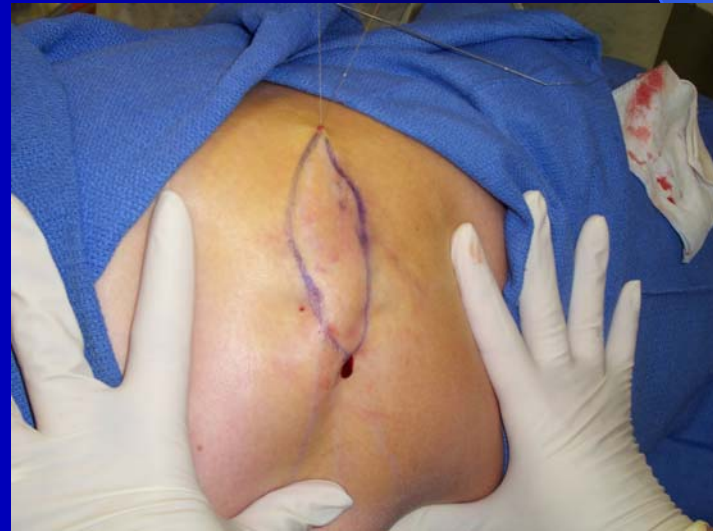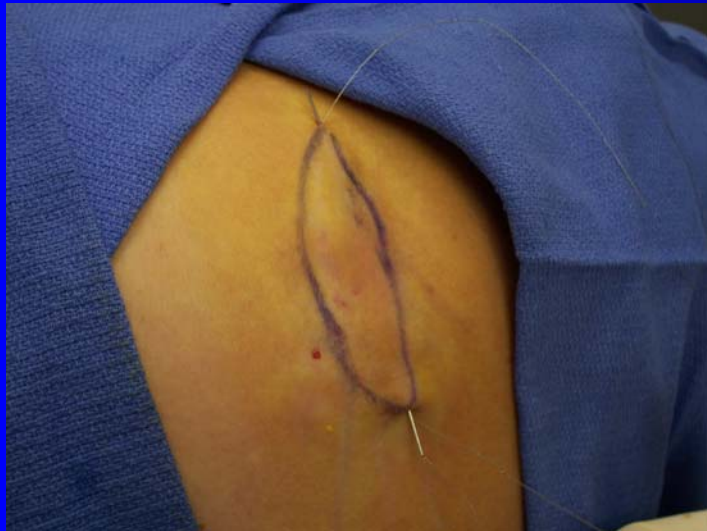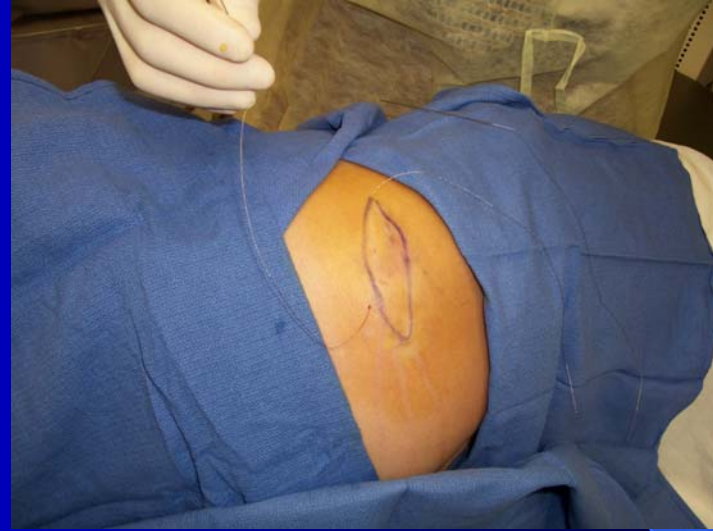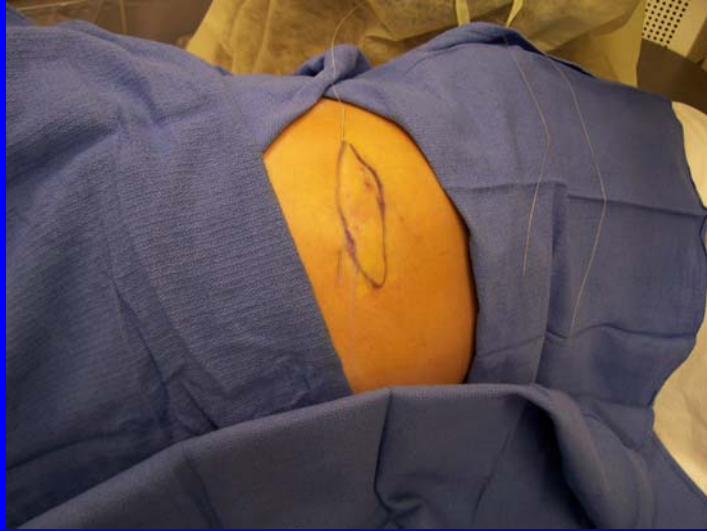Overcorrection with Fat



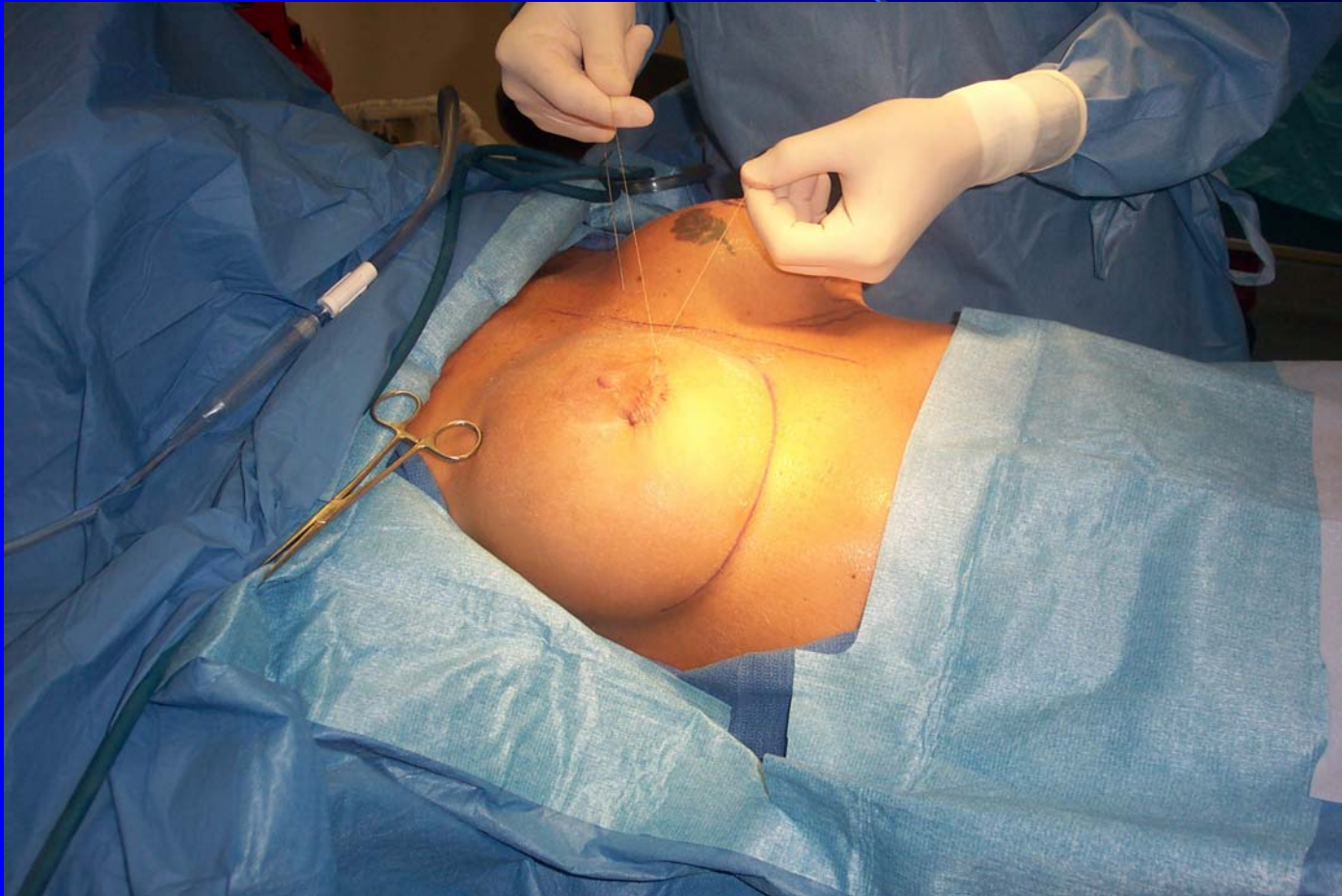Diamond Wire Subcision



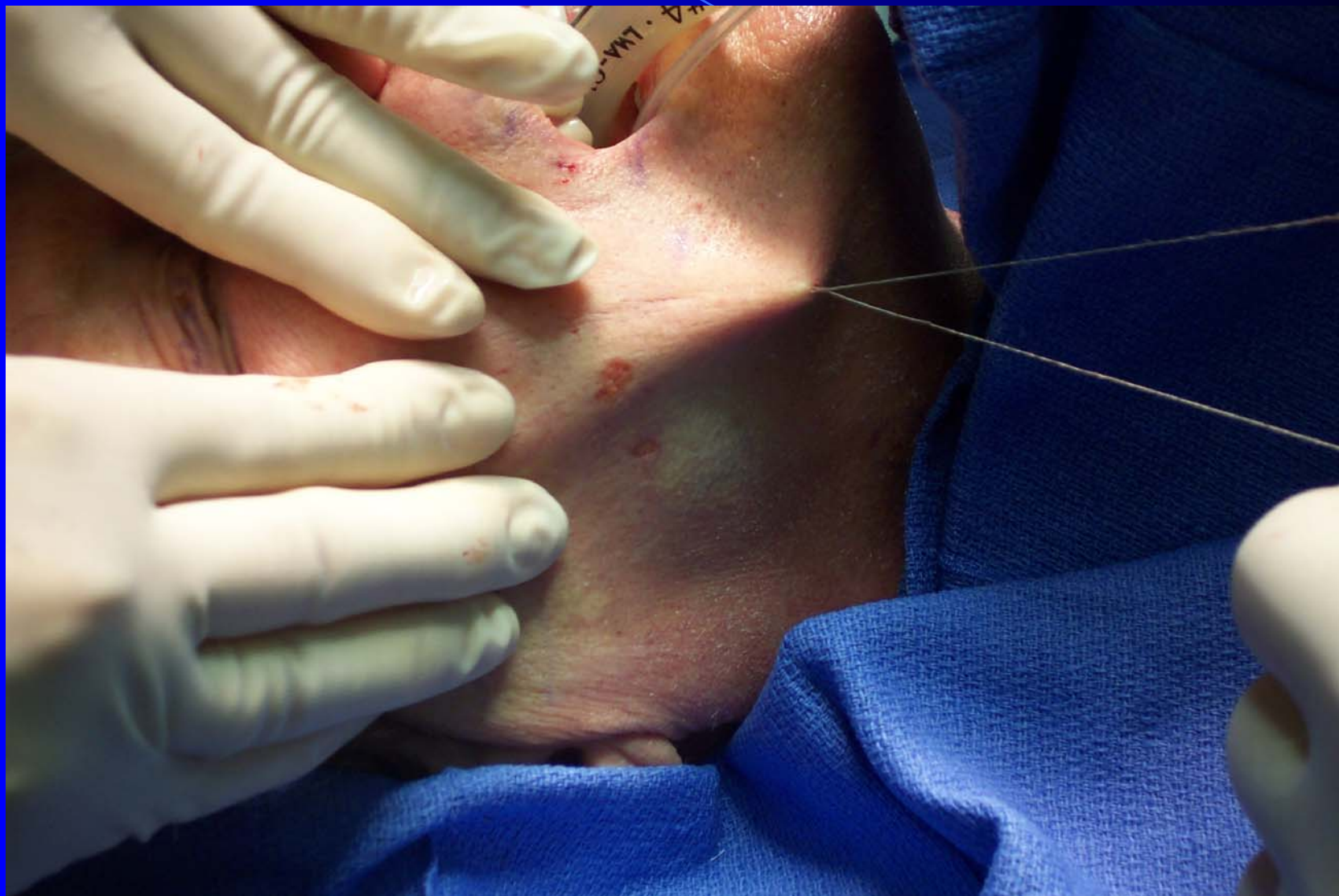Release of Buttock Depression



Release of retracted breast scar

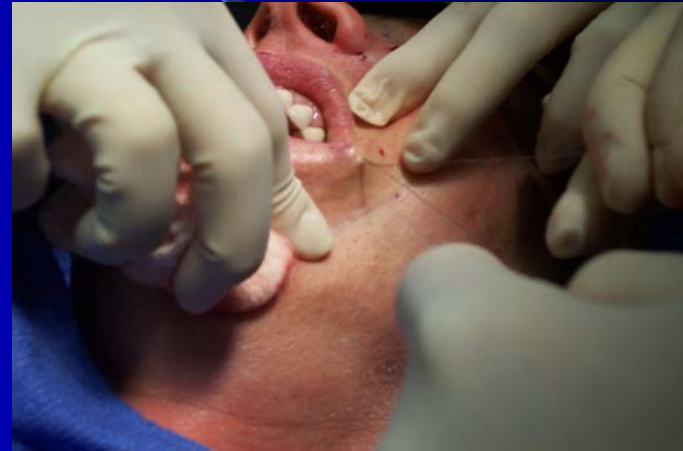
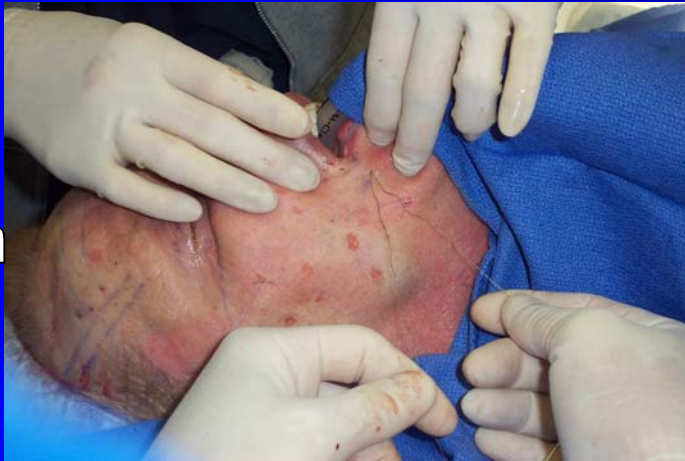
Diamond Wire release of Cheek line

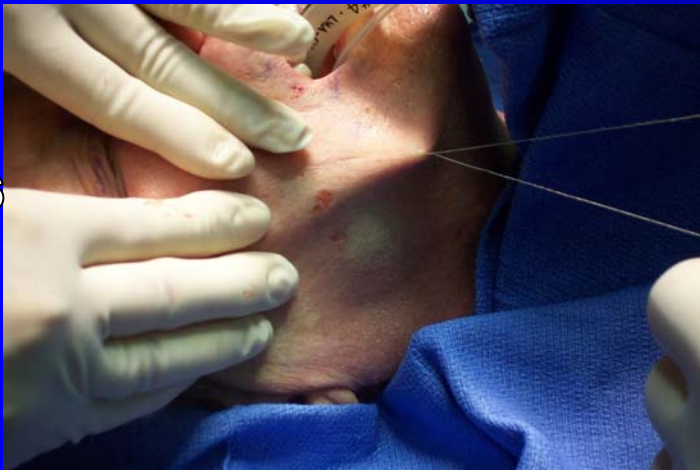

Diamond Wire Release

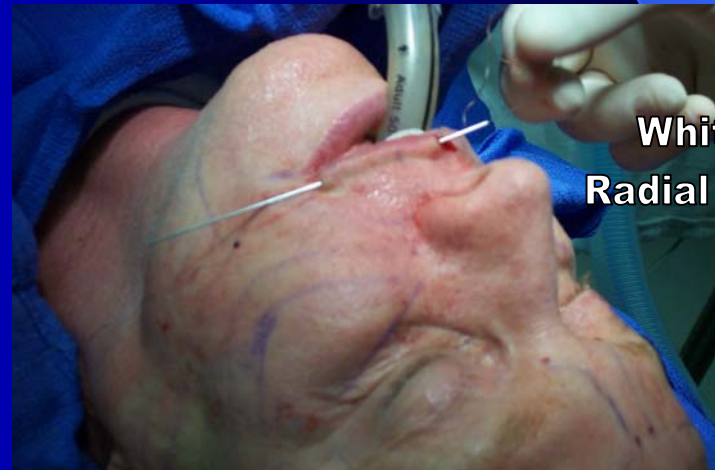Corner of mouth



Cheek lines



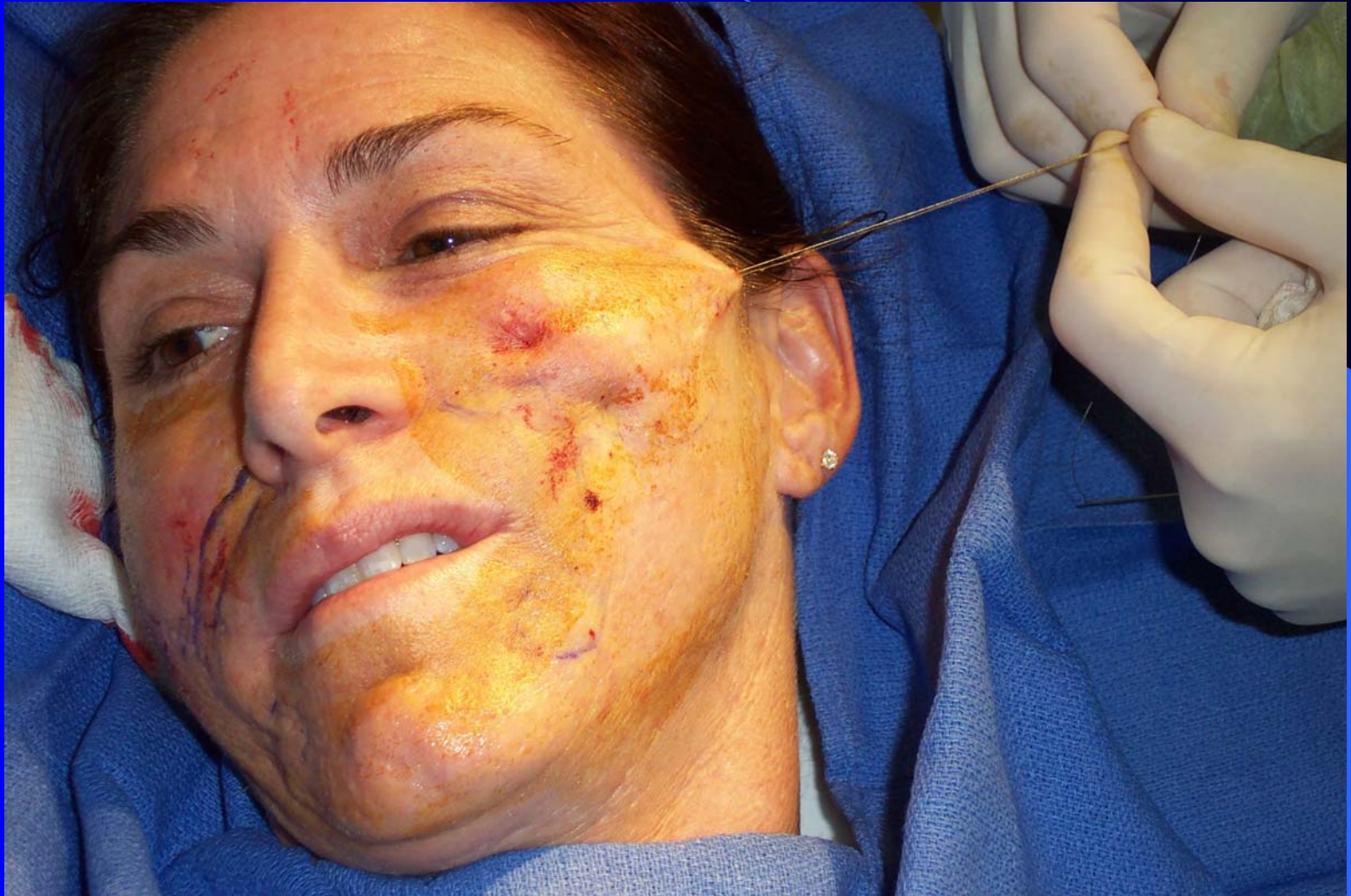White roll
Radial lip lines



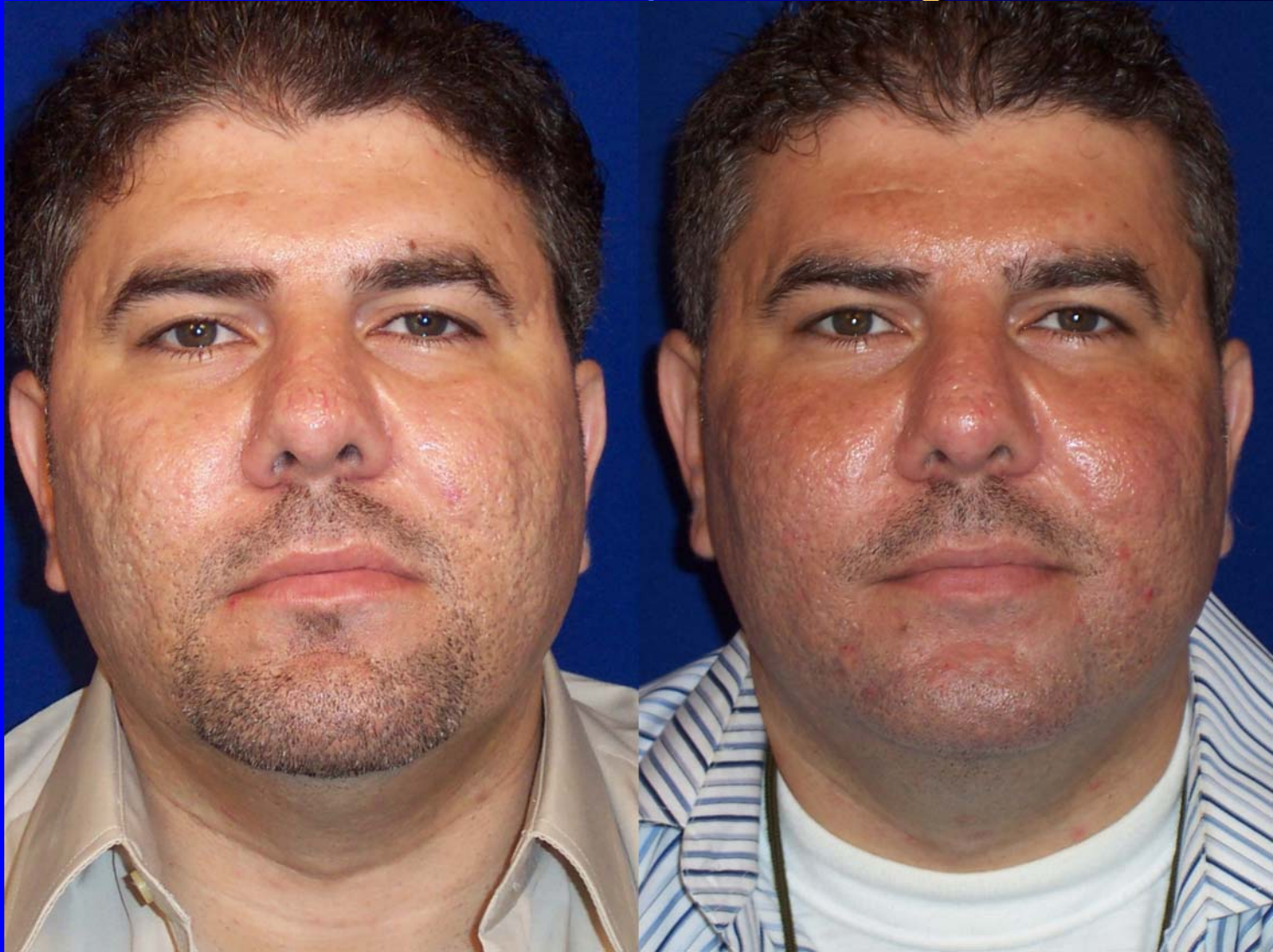7 months post Diamond Wire Release Nasolabial folds,
Radial lip lines, Glabella (**No Fat injection**)

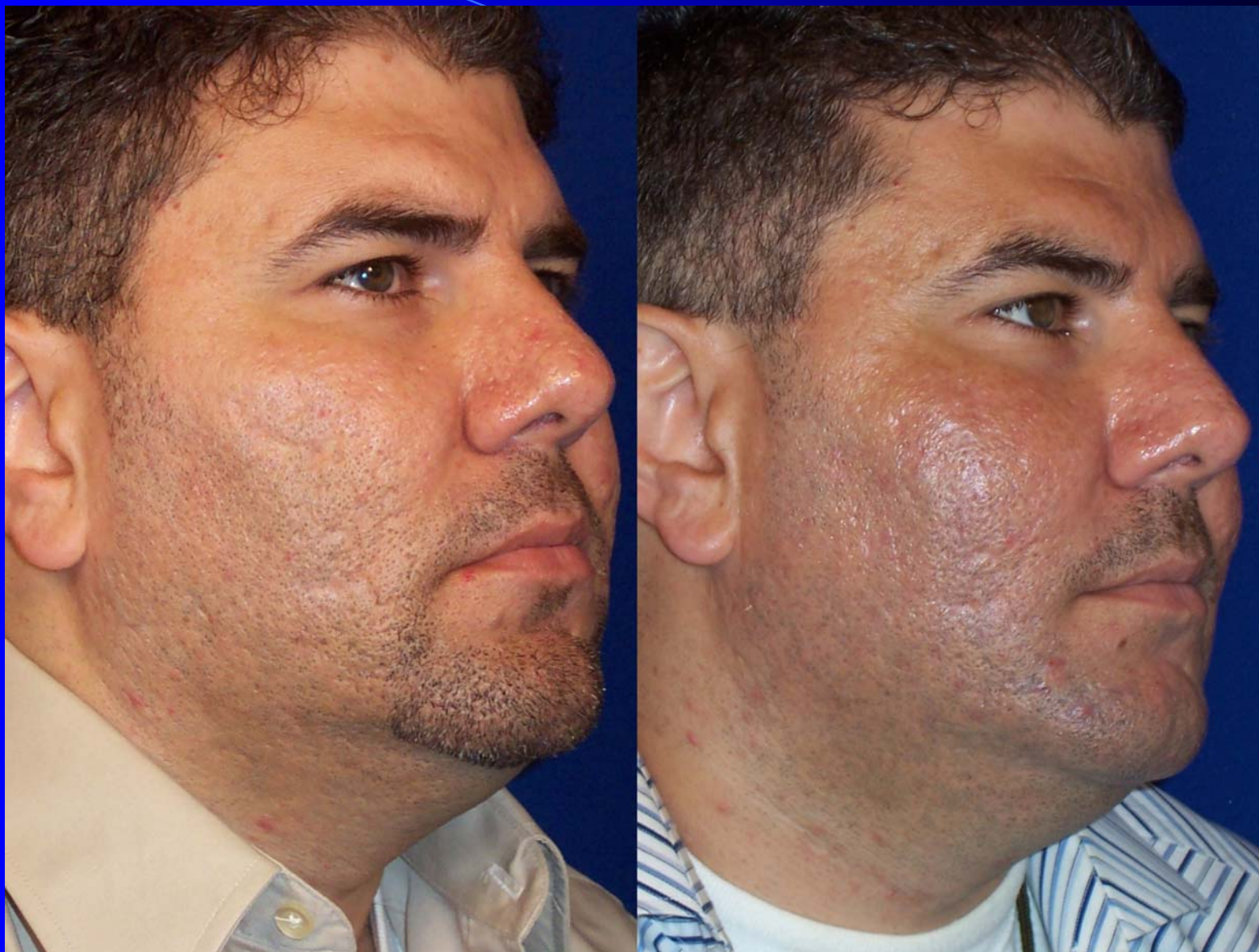

Acne Scar Cheek Release

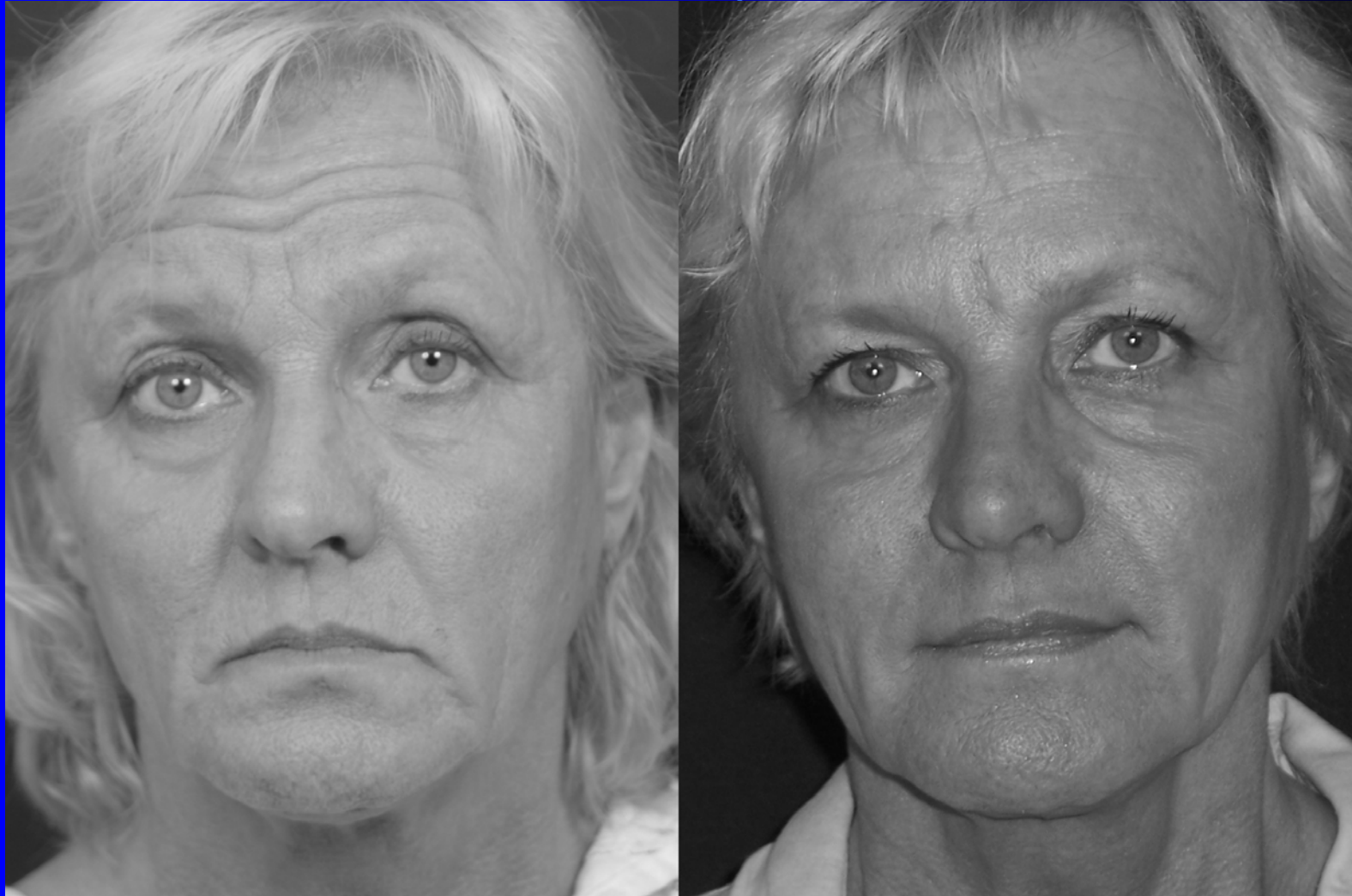

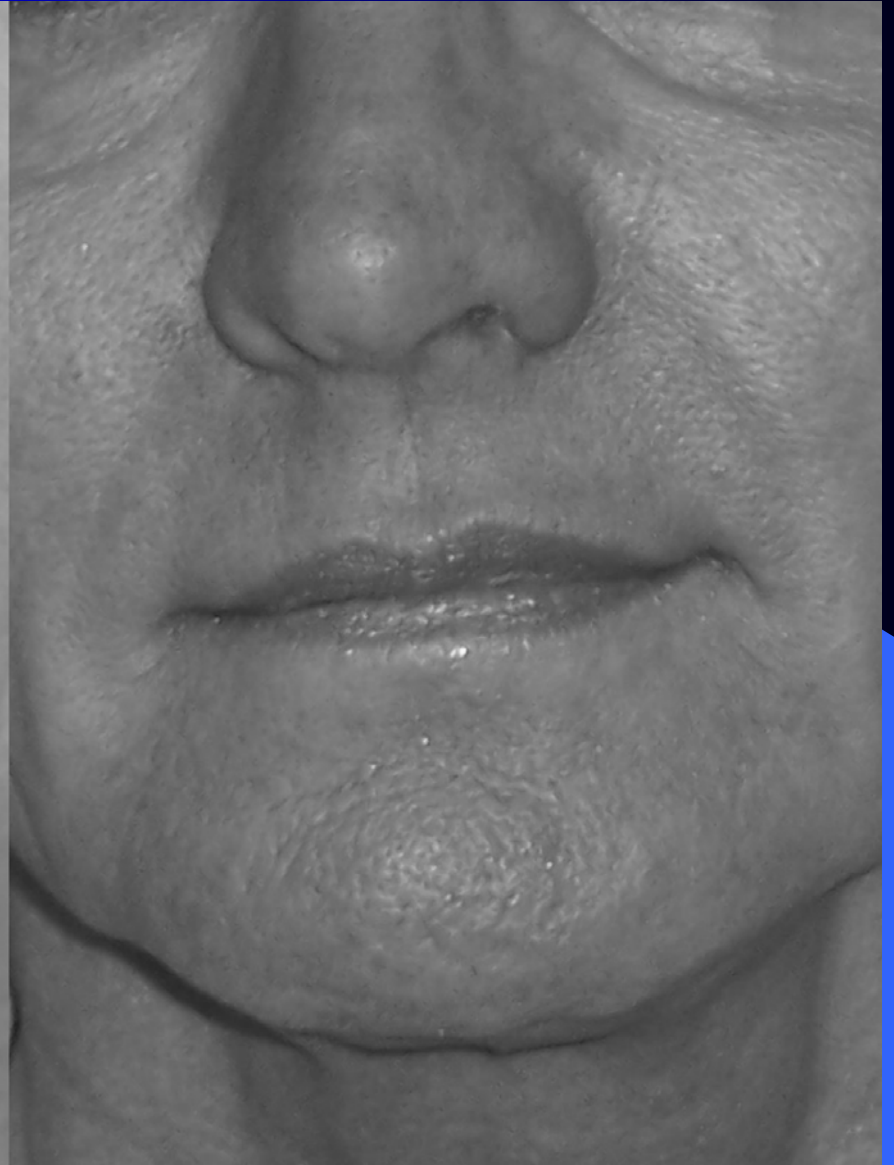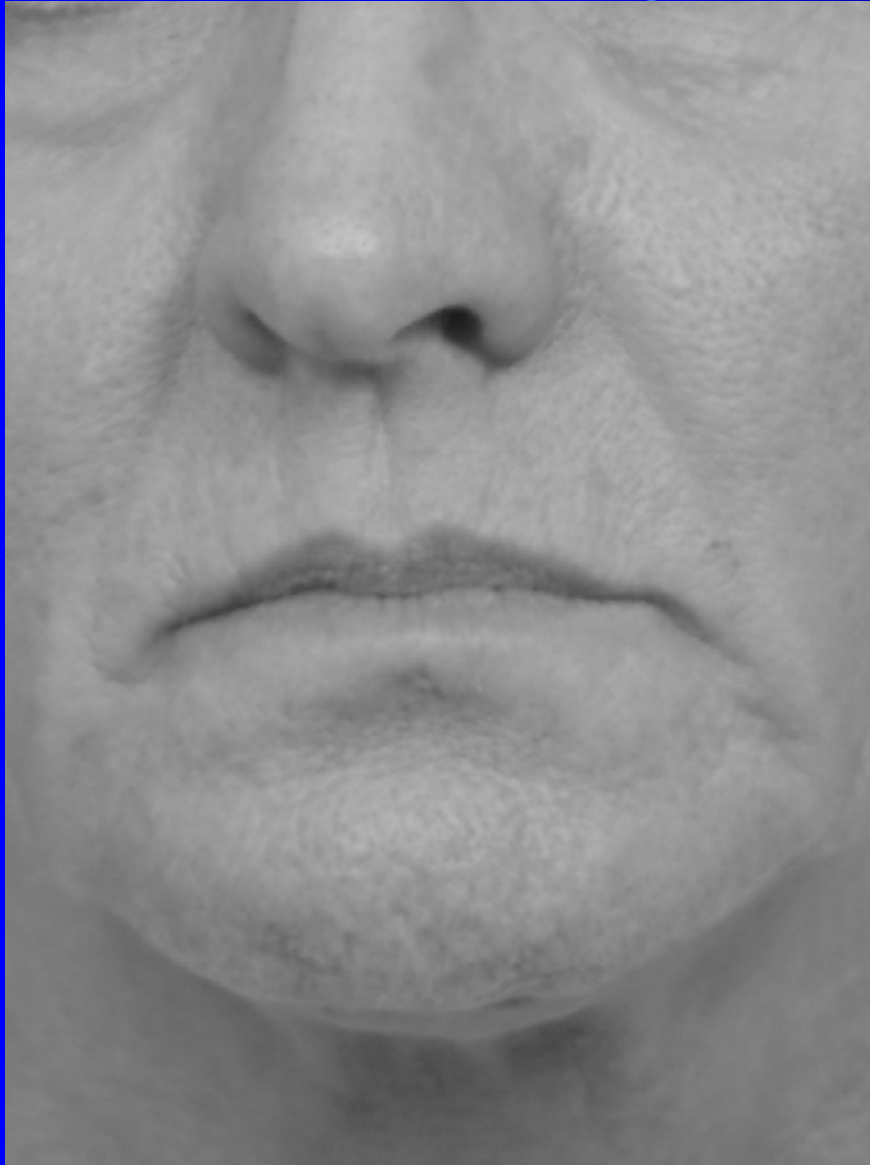Cheek Acne scar wire release + Fat injection and Laser resurfacing



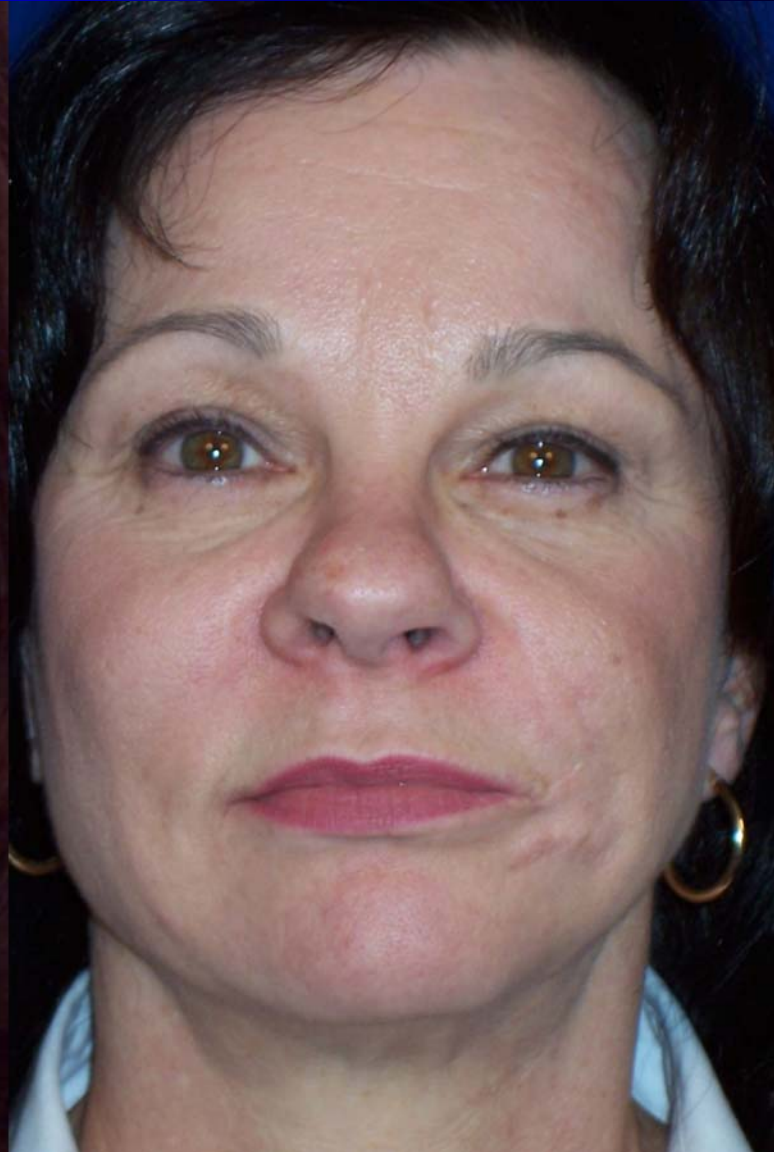

8 mos post Diamond Wire release + fat to NL/Forehead/
White roll/ RLLs/ COM/Cheek lines/Cheeks





Browlift / blephs + Diamond Wire release and
fat inj. to NL, LM, Retracted macrostomia scars



Diamond Wire Subcision: Conclusions

- *Simple, easy technique for **complete** release
of lines, folds, scars , depressions
through needle puncture site
- *Can do alone or in conjunction with other
procedures(filler/ laser , facelift,etc)
- *May not require filler...Don't overcorrect

Diamond Wire for Complete Subcision

Dr. Miles Graivier, FACS
Private Practice
North Atlanta Plastic Surgery